

HISTOLOGICAL STUDY OF DEMUCOSALIZED ILEOCYSTOPLASTY

Received 15/10/2003 – Accepted 25/09/2004

Abstract

The optimal mode of urinary tract reconstruction following cystectomy continues to challenge the urologic surgeon. We describe the experimental application and histological compatibility of the demucosalized ileum with his vascular supply, in the reconstruction of continent neobladder, after three years post operative follow up.

Keywords : Bladder augmentation, demucosalized ileocystoplasty, urology, dog.

Résumé

Le mode optimale pour la reconstruction du tractus urinaire après une cystectomie constitue un défi pour les chirurgiens urologistes. Nous décrivons l'application expérimentale ainsi que la compatibilité histologique d'une greffe de segment d'iléon vascularisée dépourvue de muqueuse, dans la reconstitution d'un nouveau réservoir continent du bas appareil, après trois ans de suivi.

Mots clés : Augmentation de la vessie, iléocystoplastie sans muqueuse, urologie, chien .

K. AMARA¹

A. NIAR¹

M. MELLIZI²

¹ Département des Sciences Vétérinaires
Faculté des Sciences Agro-Vétérinaires
Université de Tiaret (Algérie)

² Département des Sciences Vétérinaires
Faculté des Sciences
Université de Batna (Algérie)

ملخص

تعتبر الطريقة المثلى لأجل إعادة هيكلة الجهاز البولي بعد قطع جزئي للمثانة تحدياً لجراحي الجهاز البولي. هذا المقال يمثل دراسة تطبيقية وكذلك التوافق النسيجي لزراع قطعة من نسيج المعى الدقيق مع تجهيزه الدموي منزوع المخاطية، لإعادة بناء مثانة كاملة القدرات جديدة، بعد ثلاث سنوات من المتابعة.

الكلمات المفتاحية: تكبير المثانة، زرع المعى الدقيق المنزوع المخاطية في المثانة، مبحث البول، الكلاب.

Urologic procedures for bladder augmentation are performed most commonly for neurogenic bladder dysfunction or clinically contracted bladder [1]. This is done to increase the bladder capacity and lower the storage pressure between intermittent catheterization [2,11]. A wide variety of operation techniques has been described, including the use of small intestine (ileocystoplasty) [12], large intestine (colocystoplasty) [13], and stomach (gastrocystoplasty) [10,11,14]. The intestinal smooth muscle encircling intact tubular segments of intestine is capable of generating high intraluminal pressures and it is now generally accepted that bowel segments should be "detubulased" that is, opened and reconfigured as cup or patch-before being incorporated into the reconstructed bladder [3]. All of these procedures are based on isolation of a portion of gastrointestinal tract on its native vascular supply [4]. Various complications have been described arising from enteral bladder augmentation. These include electrolyte abnormalities, urinary stone disease, nutrition disturbances, hematuria syndrome, and malignancy [5,7]. To eliminate some of these complication, an international research effort is currently directed at devising effective alternative to conventional enterocystoplasty, using intestine from which the epithelium has been removed (seromuscular enterocystoplasty) [6]. To our knowledge, the technique described here is the first example successfully performed in dogs with long-term follow up.

MATERIALS AND METHODS

Two locale breed dogs, male and female weighting 15 to 20 kg, were used for the experiment. Surgical operation was carried out under general anaesthesia using atropine sulphate (1mg/b.w) intramuscularly as preanaesthetic followed 10 minutes later by intramuscular administration

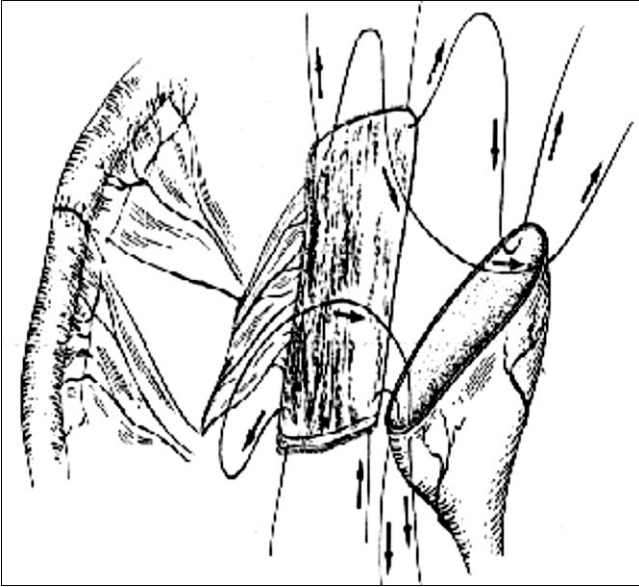


Figure 1: A segment of terminal ileum is isolated on its blood supply.

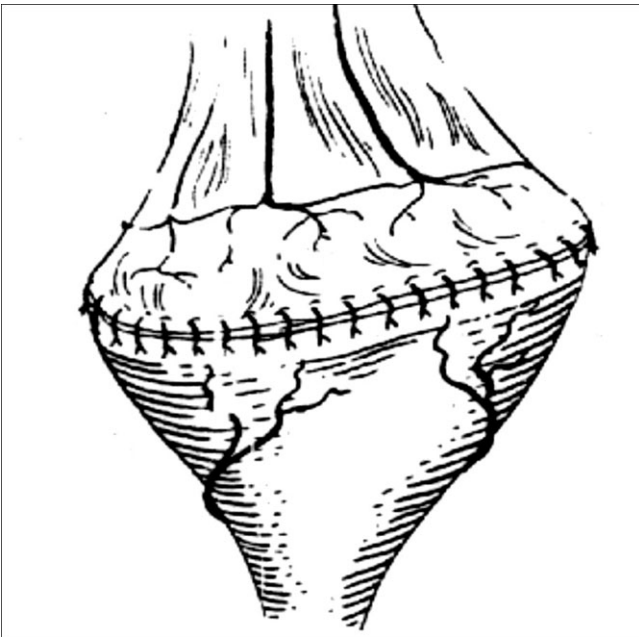


Figure 2: The segment of ileum is opened on the antimesenteric border and the patch thus is sutured to the margins of the opened bladder.

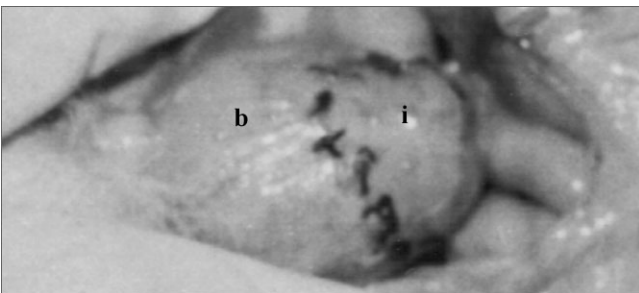


Photo A: Bladder after ileocystoplasty. We can observe the segment of ileum (i) with his native blood supply sutured to the bladder (b).

of a mixture of xylazine (5mg/kg) with ketamine (15mg/kg). Abdominal incision was performed in the middle line, post umbilical in the female dog. In the male dog, a paraprepuccial incision was used; the prepuce was retracted laterally, and a midline abdominal incision was made through the linea alba.

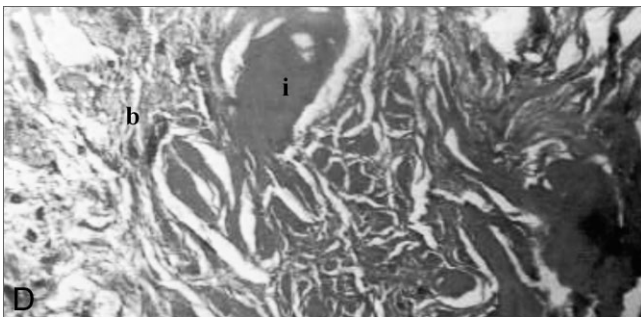
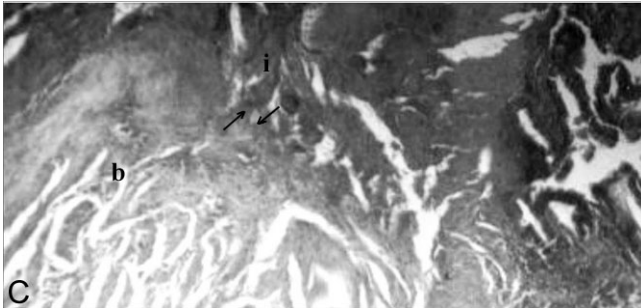
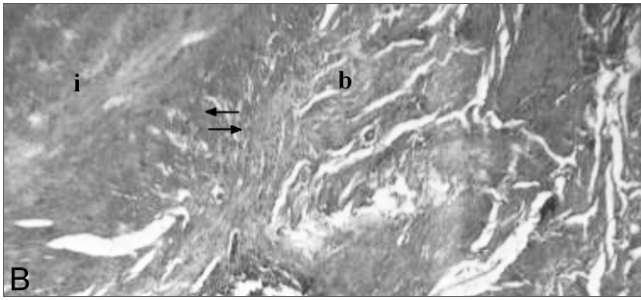
The bladder was isolated from the abdomen with moistened laparotomy towels. A retention suture was placed at the cranial end of the bladder, and a second suture was placed at the caudal end of planned incision. The bladder was emptied by cystocentesis using a 22-gauge needle and syringe. After partial resection of bladder, an ileum segment of the size of bladder defect was isolated together with its vascular supply. The intestinal segment was opened in a longitudinal fashion along its antimesenteric border; the mucosa was removed with a curette and fastened to the remaining bladder under straight tension with four fixation sutures (Fig.1). After complete suturing with interrupted 0 chromic catgut sutures (Fig.2; photo A), the intestinal edges were joined by end to end anastomosis with simple interrupted 2-0 polyglactin 910 (vicryl). The abdominal closure was carried out in the usual manner. Fluid and electrolyte deficits were corrected and antibiotic therapy was continued in the postoperative period. The bladder has been kept empty for 2 to 3 days by intermittent catheterization. After 24 hours, gradual feeding has been started.

The animals were studied after 3 years. The dogs were sedated with intravenous sodium pentobarbital (60 mg/kg). Samples of the anastomotic area, bladder and intestinal cloth were taken for histological evaluation. This last has been performed by staining paraffin slides with hematoxylin-eosin.

RESULTS AND DISCUSSION

The total operative time was approximately 3 hours, with minimal blood loss and no intraoperative complication. Our experimental dogs survived to the third year. Postoperatively, both dogs have an uneventful recovery. Resumption of physical activity and oral intake occurred on postoperative days 1 and 7, respectively. The performance of ileocystoplasty requires adherence to basic surgical tenets and must include the following basic prerequisites: (a) atraumatic mobilization of the bladder, (b) isolation and exclusion of an appropriate length of ileum on the broad, well-vascularized mesenteric pedicle, (c) re-establishment of bowel continuity, (d) construction of tension-free, muscular-to-muscular ileovesical anastomosis and bladder stenting, and (e) proper reconstruction of the stoma.

The histological sections taken through the anastomoses between the bladder and demucosalized intestinal segment showed a complete integration of cloth intestinal with the bladder (photos B, C, D). We can also observe that the demucosalized ileum incorporated in the bladder has conserved his structure (photo E). The demucosalized ileocystoplasty has re-established the bladder capacity as well as the original bladder cloth has not been affected (photo F).



Photos B,C,D: Histological findings of ileocystoplasty. Hematoxylin-eosin slide of anastomosis area seen under low power (8.5x). The arrows delineate the anastomosis between intestinal tissue (i) and bladder (b) (photos B, C). We can observe in the transversal section the fusion of the muscular layer in bladder (photo D).

Surgical treatment of patient with a neurogenic or congenitally malformed bladder has moved from incontinent urinary diversion to continent reconstruction to allow independence from external devices. This is important for the physical and social well being of human [5]. Different bowel segments have been used with variable results and complication rates [7]. Short and long term complication such as mucus production, stone formation, spontaneous perforation, metabolic disturbance, bacteriuria, and malignancy can mostly be attributed to the fact that intestinal epithelium is poorly adapted to prolonged contact with urine [3]. In the present study, we have demonstrated that the use of demucosalized ileum for auto augmentation has decreased these complications.

After resection of large portion of small intestine, maldigestion, malabsorption, diarrhoea induced by fatty acids or bile salts, bacterial overgrowth, and gastric hypersecretion may occur. The anorexia or vomiting in the presence of fever, and abdominal tenderness, indicate anastomotic leakage and peritonitis [9]. In our study, non complication related to the partial resection of ileum has been observed. Others have described bladder augmentation

using demucosalized stomach but long term follow up has not been established. Our operation technique provides adequate working space to perform the reconstruction with minimal potential for devascularization injury of the augmented bladder.

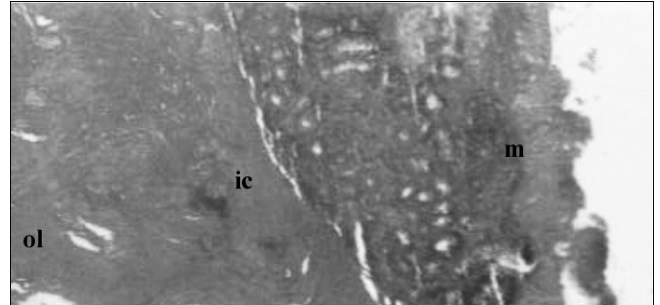


Photo E (Gx8.5): We can observe in this slide taken from the intestinal grafts that the mucosa has not been completely destroyed and the muscular layer is entirely conserved.

- (ic) internal circular layer of the muscularis
- (ol) outer longitudinal layer of the muscularis.
- (m) mucosa.

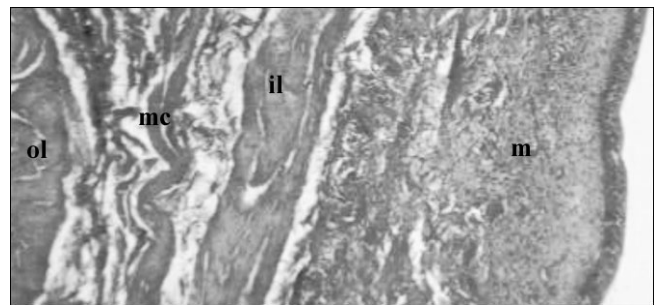


Photo F (Gx8.5): Slide of bladder tissue showed normal constitution.

- (ol) outer longitudinal layer of the muscularis.
- (mc) middle circular layer of the muscularis.
- (il) internal longitudinal layer of the muscularis.
- (m) mucosa.

CONCLUSION

Augmentation cystoplasty plays a central role in establishing a low pressure reservoir, but attention to upper tract drainage and continence are equally important. The complication and reintervention rates are relatively high. Long-term follow-up is necessary because of the persisting potential for problems. The small intestine segment is suited for use as autologous tissue substitute to cover defects of the liver, kidneys, spleen, abdominal wall and bladder, and can be used as transplant for the oesophagus, ureter and bladder and to cover a diaphragmatic hernia.

With our limited experience, we believe that bladder augmentation using a demucosalized ileocystoplasty offers a good alternative to other surgical treatments in patients with bladder defects.

The results of our study indicate that demucosalized ileum segment can be incorporated in the bladder with no long term complication.

REFERENCES

- [1]- Smith J.J. and Swierzewski S.J., "Augmentation cystoplasty", *Urol. Clin. North Am.*, Vol 24, (1997), pp 745-754.
- [2]- Duel B.P., Gonzales R. and Barthold J.S., "Alternative techniques for augmentation cystoplasty", *J. Urol.*, Vol. 159, (1998), pp. 998-1005.
- [3]- Thomas D.F.M., "Surgical treatment of urinary incontinence", *Archives of Disease in Childhood*, Vol.76, (1997), pp 377-380.
- [4]- Bjording D.E., Howard P.E., "Urinary diversion using an isolated bowel conduit or reservoir", *Problems in Veterinary Medicine*, Vol. 1, N° 1, (1989) pp 101-103.
- [5]- Shoemaker W.C. and Marucci H.D., "The experimental use of seromuscular graft in bladder reconstruction: preliminary report", *J. Urol.*, Vol. 73, (1955), pp. 314-320.
- [6]- Atala A., Vacanti J.P., Reters A.B. and Freeman M.R., "Formation of urothelial structures in vivo from dissociated cells attached to biodegradable polymer scaffolds in vitro", *J. Urol.*, Vol. 148, (1992), pp. 658-662.
- [7]- Shekarriz B., Upadhyay J., Demirbilek S. *et al.*, "Surgical complications of bladder augmentation: comparison between various enterocystoplasties in 133 patients", *J. Urol.*, Vol. 55, (2000), pp. 123-128.
- [8]- McDougl W.S., "Complication of urinary intestinal diversion", *J. Urol.*, Vol. 151, (1994), pp. 335-337.
- [9]- Ellison G.W., "Intestinal resection and anastomosis", In: Bojrab M.J., ed. *Current techniques in small animal surgery*. Fourth edition. Williams and Wilkins company, (1998), pp 248-254.
- [10]- Perek G., Specht M., Lin D.D. *et al.*, "Hand-assisted demucosalized gastrocystoplasty comparing different tissue closure methods", *J. Urol.*, Vol. 58, (2001), pp. 625-630.
- [11]- Bleustein C.B., Cuomo B., Mingin G.C. *et al.*, "Laser-assisted demucosalized gastrocystoplasty with autoaugmentation in a canine model", *J. Urol.*, Vol. 55, (2000), pp. 437-442.
- [12]- Perito P.E., Carter M., Civantos F. *et al.*, "Laser-assisted enterocystoplasty in rats", *J. Urol.*, Vol. 150, (1993), pp. 1956-1959.
- [13]- Kato H., Igama Y., Nishizawa O. "Versatility of reconfigured-colon-segment technique for urinary reconstruction requiring use tubular structures", *J. Urol.*, Vol. 59, (2002), pp. 290-293.
- [14]- Raz S., Ehrlich R.M., Babiarz J.W. *et al.*, "Gastrocystoplasty without opening the stomach", *J. Urol.*, Vol. 150, (1993), pp. 713-715.