

THE PARATUBERCULOSIS IN THE SLAUGHTER HOUSE OF BOUSSOUF (CONSTANTINE)

Reçu le 16/11/2013 – Accepté le 22/04/2014

GHERROUCHA D¹. LAKHDARA N., TEKKOUK F., RIDOUH R., BENHAMZA L.

1 : Laboratoire gestion de la santé et production animale. Université Constantine 1, Institut des Sciences Vétérinaires El Khroub

Résumé

La paratuberculose bovine est une maladie chronique infectieuse et contagieuse due à la multiplication dans l'organisme de la mycobactérie *M. paratuberculosis*. Cette maladie est répandue dans tous les pays pratiquant l'élevage intensif des bovins et provoque de très lourdes pertes économiques. Cette étude avait pour objectif la recherche de la paratuberculose au niveau des abattoirs chez les bovins. La partie pratique consiste en des visites à l'abattoir, à faire une inspection des intestins et à prendre des prélèvements sur les ganglions mésentériques hypertrophiés accompagnés d'une partie de l'intestin et à les envoyer au laboratoire pour une étude histopathologique. Deux colorations sont effectuées, l'HE et la coloration de Ziehl à froid ; des empreintes des intestins et des ganglions mésentériques sont également colorés par la méthode de Ziehl-Neelsen à chaud et examinés au microscope.

Mots clés : Paratuberculose, bovin, abattoir, Constantine, histopathologie.

Abstract

Bovine paratuberculosis is an infectious and contagious chronic disease due to the multiplication of the mycobacterium *M. paratuberculosis* in the organism. This disease is widespread in all countries practicing intensive cattle raising and causes heavy economic losses. The objective of this study is to search for paratuberculosis in cattle in the slaughterhouses. The practical part consists on several visits to the slaughterhouse, to inspect the intestines, to take samples from the mesenteric hypertrophied ganglions, with a portion of the intestine, and to send them to the laboratory for histopathological study. Two stains were made, the HE and cold Ziehl stain; impressions of intestines and mesenteric ganglions are also colored by the Ziehl-Neelsen hot method and examined microscopically.

Keywords : paratuberculosis, cattle, slaughterhouse, Constantine, histopathology.

ملخص

ان نظير السل البقري هو مرض مزمن ومعدي، ويرجع ذلك الى الزيادة في اعضاء (*lycobactérie M. paatuberculosis*) هذا المرض منتشر بكثافة في الدول، خاصة التي تربي الماشية، كما يسبب خسائر اقتصادية فادحة. تهدف هذه الدراسة للبحث عن نظير السل البقري على مستوى المدايح الخاصة بالماشية الجزء التطبيقي يتضمن زيارات للمدايح (المسالخ) لتفقد واخذ عينات من العقد المساريقية المتضمة، مرفوقة بجزء من الامعاء وارسالهم الى المختبر من اجل دراسة تشريحية مرضية ثم القيام بالتلوين المزدوج HE وتلوين Ziehl على البار، العينات من الامعاء والعقد المساريقية أيضا لونت بنفس الطريقة لـ Ziehl-Neelsen على الساخن وتمت دراستها مجهرياً.

الكلمات المفتاحية : نظير السل، الماشية، المسلخ، التشريح المرضي، قسنطينة

The paratuberculosis (Johne Disease) is a bacterial disease (due to a bacteria called *Mycobacterium avium*, subspecies paratuberculosis (MAP)), a contagious chronic disease of the intestine. It affects commonly not only the domestic ruminants but also several wild species (AFSSA, 2009; McClure *et al.*, 1987). It is described in all continents; even though our country seems to be free, the risk of the occurrence of this disease remains possible due to commercial exchanges. This digestive affection is characterized by a cachexia of slow evolution and a diarrhea that becomes more and more severe (Brugere-Picoux, 1987; Vialard, 2007; Chastel, 2008; Afssa, 2009; Brugere-Picoux, 2012; Houtain, 2012).

The lesions of paratuberculosis could be found in the liver and the heart however they are observed frequently in the intestine, the ileocecal valve and the mesenteric ganglions.

The paratuberculosis can be diagnosed with a superficial examination of intestine to observe signs of thickening and with histopathologic examination to see the epithelioid cells and the giant cells of Langhans (Cherel *et al.*, 2006; Afssa, 2009).

As this affection may not express in cattle, even in advanced stages, the diagnosis is usually done after slaughtering by a post mortem exam. Thus for a preliminary detection of the paratuberculosis, the slaughter house may play a very important role.

The aim of our study is to search the paratuberculosis in the municipal slaughter house of Boussouf Constantine.

MATERIAL AND METHODS

In the slaughter house

The entire work was done in the slaughter house of Boussouf, located in the western suburbs of Constantine, we have withdrawn information during various periods: 23 December 2012 to 2 January 2014, 12-26 September 2013.

The animals which have been the subject of the study are in number of: 48 cattle of local and imported breeds (black pie, red pie, Montbeliarde and charolais breeds), aged from 10 months to 10 years, of male and female sex.

Material used in the slaughter house

A pair of scissors, blade of bistort, a blade of knife, a pot of histological samples, an information sheet, a camera.

- After slaughtering and before dressing of animal, all the information concerning the animal are taken (breeds, sex, and age).

- after the opening of the thoracic and the abdominal cavity, a complete examination of the other viscera (particularly the liver) and the carcass is done in order to detect other lesions related or not with the initial lesion if it exists.

- The intestine as well as the mesenteric ganglions are examined deeply, the eventual lesions are described according to their localization their extend and their macroscopic description.

-after rinsing the intestine, the needed samples are performed.

For the hisopathological analysis, samples of 1 cm were realized with a scalpel, thoroughly not to alter the architecture of the organ, it interested the ileocecal papilla, a part of the ileum (30cm upstream of the ileocecal valve) (Durand, 2001), of the jejunum, and the mesenteric ganglions.

The samples were placed in a solution of formaldehyde at 10%. The samples are put into samples' pots previously labeled, before sending to the laboratory for histopathological analysis.

An imprint of intestine and mesenteric ganglions of 10 animals (for the 30-40 cases) for the hot Ziehl stain (Cherel *et al.*, 2006; OIE, 2008).

In the laboratory

Material

It is the classic material of a laboratory of histology as: Paraffin distributor, microtome, an oven, histological platinum, optic microscope, various chemical products: formaldehyde at 10%, alcohol 100%, toluene, Canada balsam, dyes (hematoxylin, eosin), paraffin, Bouin solution, sulfuric acid, bleu of methylene, fuchsine Ziehl. In the laboratory, the samples fixed in formaldehyde at 10% are registered before identification.

Steps from samples to blocks

Fixation

The objective is the preservation of the structures, hardening of tissues, formaldehyde and Bouin solution were used upon the availability of chemical products (Antoine, 2010; Banks, 1993; Sandritter, 1974).

Circulation

Dehydration in three alcohol baths. Brightening in three baths of xylene.

Impregnation

Samples are poured in a first paraffin bath, put overnight at 56°C.

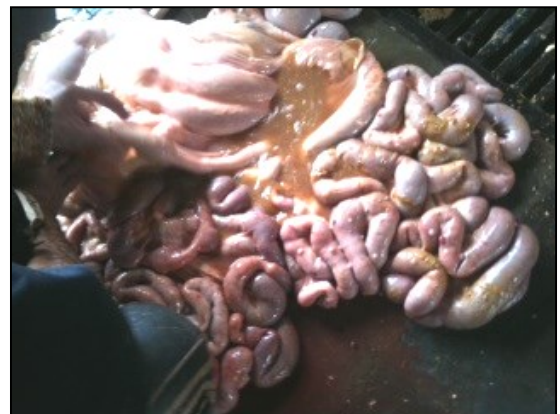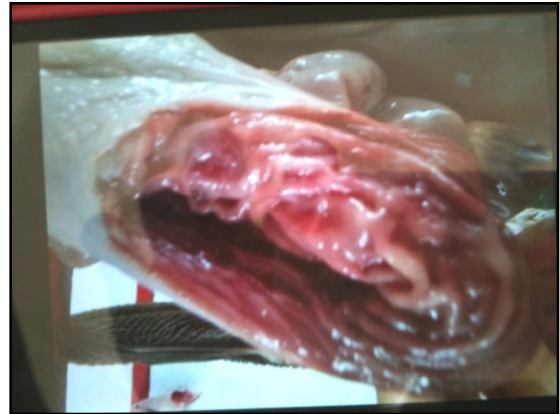Block layout: It is a step that consists on giving an external support allowing the realization of sections by microtome.

Sections in microtome

Sections are done in a motorized cutting mode by a step of 4 to 5 mm of thickness after roughening by a step of 20 mm until reaching the tissue fled into the paraffin by increasing progressively the speed.

Staining or colorations

Two staining were used (HE, Ziehl at cooling). The frotis of the affected mucosa and sections of the mesenteric lymph nodes should be stained by hot Ziehl-Nielsen method and examined microscopically



Case n°06: *Typhlitis* Case n°10: *Oesophagostomus*

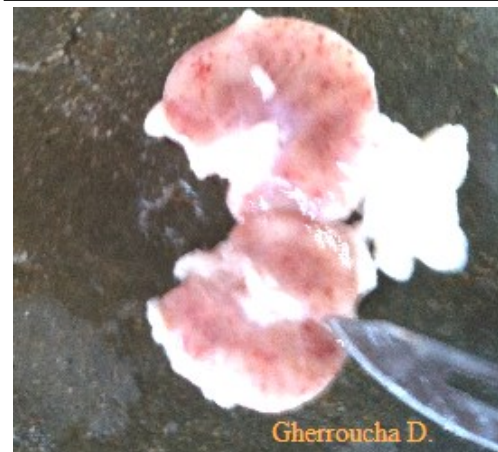
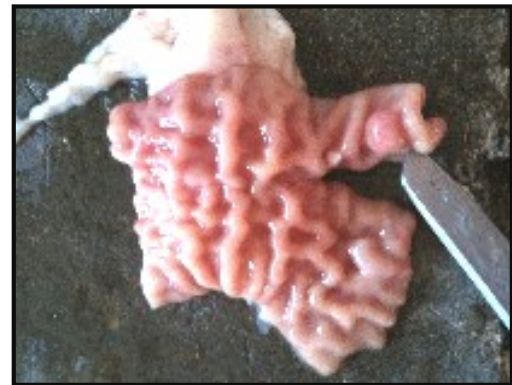RESULTS

Macroscopic lesions

Among the 48 cases, we did not observe any intestinal lesion corresponding to that of paratuberculosis as chronic granulomatosis, enteritis of cerebroid aspect or granulomatous lymphadenitis. However, we have identified other lesions among them we can cite: oesophagostomous and the typhlitis (intestine), cutaneous papillomatosis (head) and adipoxanthosis (carcass).

Table 1: macroscopic lesions observed in the slaughterhouse

Case number	macroscopic lesions
Case n°06	<i>Typhlitis</i>
Case n°09	Warts in the head
Case n°10	<i>Oesophagostomus</i>
Case n°13	<i>Adipoxanthosis</i>
Case n°24	<i>Adipoxanthosis</i>
Case n°37	Intestinal granuloma <i>Petechiae</i> in the mesenteric ganglion



Case n°37: Intestinal granuloma *Petechiae* in the mesenteric ganglion

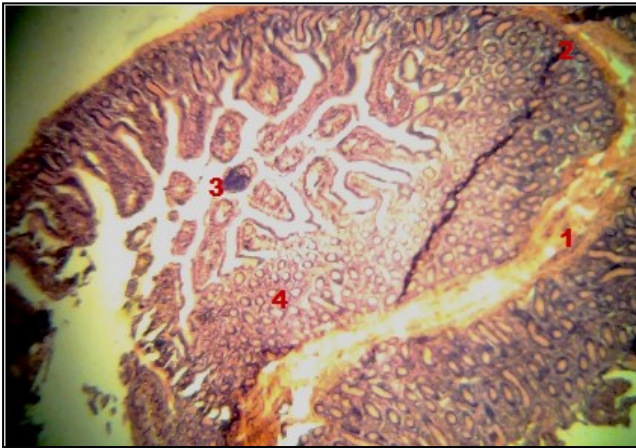
Staining HE

In the results presented in table 1, no pathognomic lesion of paratuberculosis was found as lesions of granuloma, isolated giant cells of Langhans ...

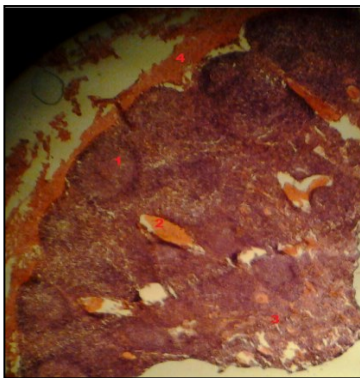For many blades, this small intestine wall has a conserved mucosa (mucosa subnormal).

In many blades of intestine and particularly the ileum, this wall is also the place of anonspecific inflammatory infiltrate composed of a slick of lymphoplasmocysts, extended from corium to serous. It is a nonspecificsub-acute enteritis.

Concerning the ganglions, a lymphocyte hyperplasia is noticed.



1 :Submucosa, 2 :Artifact (folds), 3 :lumen, 4 : LieberkuhnGland
Case n°37: Ileitis.



1- Lymphoid follicle, 2- Hemorrhage 3- Medulla, 4-Capsule

Case n°37: Mesentericlymphnodes

Ziehl Nielsen staining : The blades submitted to hot Ziehl Nielsen are negative. However, those submitted to

cold Ziehl Nielsen can not be interpreted.

Table n°2: Results of the techniques used

Number of animalsexamined	Number of blades made
48	56 blades
10	19
10	20
Analytical technique used	Results
HE	- Subnormal mucosa - Six Cases of inflammation of the jejunum, ileum and ileocecal valve: enteritissub-acute nonspecific
cold Ziehl Nielsen	can not be interpreted
hot Ziehl Nielsen	Negative

DISCUSSION

Histological analysis has not revealed pathognomonic lesions of the disease like granulomas, giant cells of Langhans, small groups of macrophages and giant cells of corium and the submucosa spread in the paracortical zone of the mesenteric lymphatic nods, and when the lesions are severe, several macrophages and giant cells infiltrate all the layers of the intestinal wall and the light of lymphatic vessels.

The diffuse infiltration of the corium of the intestinal mucosa by epithelioid cells induces thickness of intestinalvills and Lieberkuhn glands undergo an atrophy by compression (OIE, 2008).

This can be explained by many hypothesis. Taking into account our knowledge about the climate of the region of Constantine, which is a Mediterranean climate between subhumide and subarid, (Anonyme , 1988) not suitable for the survival of MAP.

Moreover, it is well known that specific lesions of paratuberculosis arehypertrophia of the intestinal mucosa with transversal ridges visible in the internal side, an edema, a lymphangitis and a mesenteric adenopathy. Unfortunately, these characteristic lesions are absent.

Our negative results could be explained by the non-targeting of animals, it is found that the dairy cow highly productive is, an animal typically affected by paratuberculosis due to its high fragility (Radostis, 2000).

The negative results may be due to the conditions of veterinary inspection at the slaughter house (in fact, the examination of the intestine is not obvious). Moreover the small size of the sample as well as the nonoccurrence of this disease in the region of Constantine could explain these negative results.

By comparing our results to those reported in the literature we can find that for instance in USA, the analysis of the ileocecal lymphatic nodes taken from cattle in slaughterhouse revealed a prevalence of 1.6%. However, the prevalence in some states as Wisconsin reached more than 10.8% in the dairy livestock.

In UK, 15% positive cases were observed at the slaughter house, in 1998 from 1985 to 1994 a prevalence of 4.9% was observed (Gounot, 2000).

Our results are similar to those reported by Soualem and Aloun. 2009. Who did not show any positive case after the histological analysis undertaken in about 40 samples (cattle, sheep and goats) sampled in the slaughter house of AinAssel and Boutheldja (Soualem, Aloun, 2009).

Though these negative results, the occurrence of paratuberculosis in Algeria is proven in many studies. The results of a survey conducted in 2006, confirmed the presence of the affection in cattle.

In the eastern part of Algeria, Ouchtati (2009) reported a prevalence of paratuberculosis equal to 10,6%, the national prevalence being equal to 11,66%.

A serologic screening conducted in 7 dairy cows livestock in the wilayas of Annaba, Souk Ahras and Taref showed that among 180 cows, 20 answered positive to the serological test with a prevalence equal to 11,11% (Ouchtati, 2009).

CONCLUSION

The aim of our study was to highlight the presence of paratuberculosis from samples taken at the slaughter house mainly from the terminal ileum, the ileocecal junction and the mesenteric lymphatic nodes.

Slides submitted to histopathological exam did not show any specific lesion of paratuberculosis, intestinal

walls morphology are preserved or show nonspecific enteritis.

It should be noted that this disease occurs in Algeria even though our results are negative probably because of the size of the samples, moreover the slaughtered animals are mainly fattened calves well maintained and in a good health.

The paratuberculosis undergoes its dissemination in livestock and in countries especially because the cost of the control is more important than the disease.

REFERENCES

- [1]- AFSSA (2009). Paratuberculose des ruminants Mars, Édition AFSSA.
- [2]- ANTOINE N. (2010). Université de Liège, Faculté de Médecine Vétérinaire, Service Histologie, communication personnelle.
- [3]- ANONYME (1988). Monographie de la Wilaya de Constantine. Minis. Hyd. Et de l'Env. et des forêts, 1 : 1-117.
- [4]- BANKS W. (1993) Applied Veterinary Histology. 3th ed. Saint Louis (USA): Mosby, 527p.
- [5]- BRUGERE-PICOUX J. (2012). Actualités sur la paratuberculose bovine Bull.Acad.Vét. France, tome 165,1
- [6]- BRUGERE-PICOUX J. (1987). Le diagnostic de la paratuberculose chez les ruminants. Rec.Méd. Vet,163,539-546
- [7]- CHASTEL M. (2008). Epidémiologie de la paratuberculose des ruminants : conséquence sur les mesures de contrôle et de prévention. Thèse Ecole Nationale Vétérinaire de Toulouse.
- [8]- CHEREL Y. *et al.* (2006). Autopsie des bovins. Les éditions du point vétérinaire. Dépôt légal : septembre 2006, chapitre IV : Tableaux nécropsiques des principales affections des bovins. La paratuberculose 113,114.
- [9]- DURANT L. (2001). Etude du dépistage de la paratuberculose caprine à l'aide d'un test ELISA Thèse Ecole Nationale Vétérinaire de Lyon.

- [10]- GOUNOT G. (2000). La paratuberculose et le plan national de maîtrise de cette maladie en élevage infecté, P 44.
- [11]- HOUTAIN J. (2012). La paratuberculose bovine, la maladie le plan de contrôle (industrie laitière) le plan de lutte, service épidémiologie et administration de la santé ; ARSIA édition
- [12]- McCLUREH.M., CHIODNI R.J. et ANDERSON D.C. (1987). *Mycobacterium paratuberculosis* infection in a colony of stump tail macaques (Macaca arctoides). *Journal of Infectious Diseases*. **155** (5), 1011-1019
- [13]- OIE, (2008). Manuel des tests de diagnostic et des vaccins pour les animaux terrestres (mammifères, oiseaux et abeilles) Sixième Édition Volume 1 chapitre 2, 1,11 : paratuberculose (maladie de johne). <http://www.oie.int/fr/normesinternationales/manuel-terrestre/acces-en-ligne/> consulté le 22-08-2013
- [14]- OUCHTATI I. (2009). Prévalence de la paratuberculose bovine dans sept cheptels bovins laitiers dans les wilayas d'Annaba, El Taref et Souk ahras (Enquête sérologique), Projet de fin d'étude, Institut Vétérinaire El Taref.
- [15]- RADOSTIS (O.M), GAY (C.C), BLOOD (D.C), HINCHCLIFF (K.W). (2000). *Veterinary medicine*, neuvième édition, Saunders Editeur, 920-934.
- [16]- SANDRITTER W. (1974). *Manuel et Atlas d'histologie*. 4^e émeed. Paris : Masson et Cie, 306P.
- [17]- SOUALEM A., ALOUN B. (2009). Contribution à la fréquence de la paratuberculose chez les ruminants des deux Wilayates d'El Tarf et de Souk Ahras, diagnostic histo-anatomopathologique. Mémoire de fin d'étude el-Taref.
- [18]- VIALARD J. (2007). Unité de pathologie infectieuse école nationale vétérinaire de Lyon. Paratuberculose et maladie de crohn similitudes et différences